XX Jornadas Internacionales de Traumatología del Deporte

SETRADE
SOCIEDAD ESPAÑOLA DE TRAUMATOLOGIA DEL DEPORTE

ABORDAJES TERAPEUTICOS EN LAS TENDINOPATIAS II:

"CIRUGIA".

Dr. C. Sánchez Marchori. **csanchez@valenciaport.com**

CIRUGIA DE LAS TENDINOPATIAS

- Tendinopatia:

Corresponde a cualquier afección tendinosa.

- No confundir con: Entesopatia, que se refiere a la inserción y NO únicamente a las fibras tendinosas.

USA

- 33 millones de lesiones musculo esqueléticas.
- 45% de partes blandas.
- 30.000 reparaciones tendinosas.

↑ $ ↑ €

De Franco M, Derwin K, Iannotti J. J Am Acad Orthop Surg 2004;3:370-376

"…afecta a millones de personas en el mundo amateur y profesional con graves consecuencias de rendimiento y económicas…"

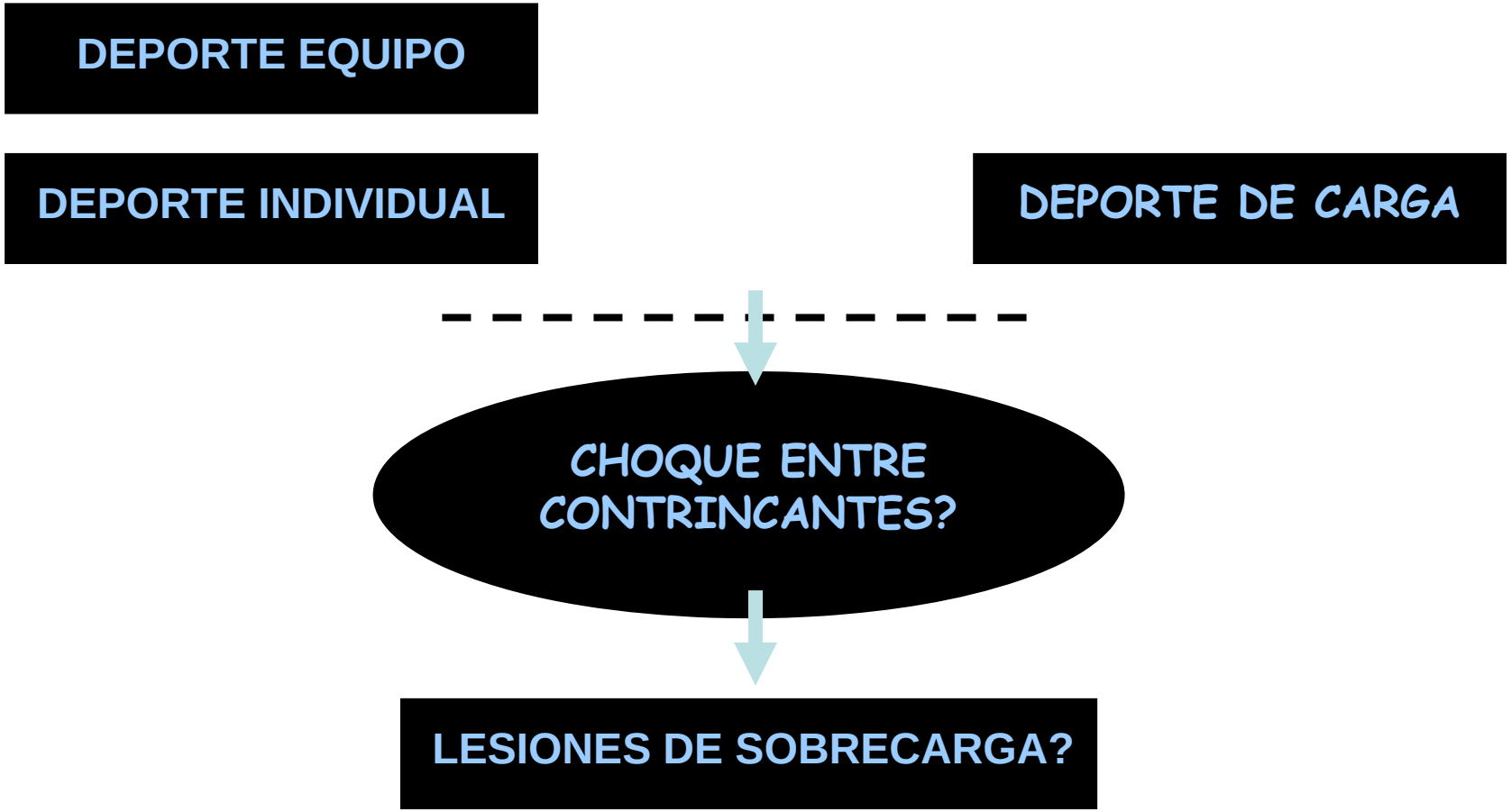

CONTROVERSIA ??

Maffulli N, Kader D. Tendinopathy of a. tendon. *J Bone Joint Surg Br* 2002; 84:1-8

Murray I, Mckenzie K, Coleman S. How evidence based is the management of two common sports injuries in a sports injury clinic. *British Journal Sport Med* 2005Dec: 39:912-6

“Cuando una cosa deja de ser un tema controvertido, deja de ser un tema de interes”. HAZLITT.

Respuesta adaptativa a CAMBIOS en las fuerzas mecánicas



PATOLOGÍA DE LOS TENDONES

CURRENT CONCEPTS REVIEW

TENDON INJURY AND TENDINOPATHY: HEALING AND REPAIR

THE JOURNAL OF BONE & JOINT SURGERY · JBJS.ORG
VOLUME 87-A · NUMBER 1 · JANUARY 2005

BY PANKAJ SHARMA, MRCS, AND NICOLA MAFFULLI, MD, MS, PHD, FRCS(ORTH)

2005

- **Fuerzas que actúan son diversas.**
  - Tracción.
  - Pinzamientos.
  - Rozamientos.

Rotuliano. Aquiles
Manguito rotador.
Tibial posterior.
Peroneos.

Repeated Exposure of Tendon to Prostaglandin-E_2 Leads to Localized Tendon Degeneration

Mustafa H. Khan, MD, Zhaozhu Li, MD, and James H.-C. Wang, PhD (*Clin J Sport Med* 2005;15:27–33)

- Estudios:
  - Implantando dispositivos en tendones animales y humanos.
  - Empleo de métodos alternativos: US, RMN.

Respuesta biológica a las fuerzas

Identificación de las tendinopatías

Resolución de la sintomatología

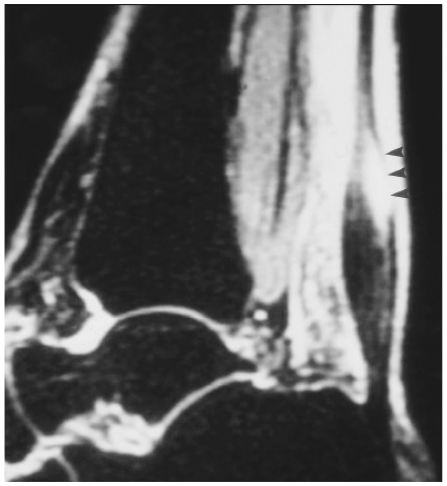

Identificar y corregir los factores causales

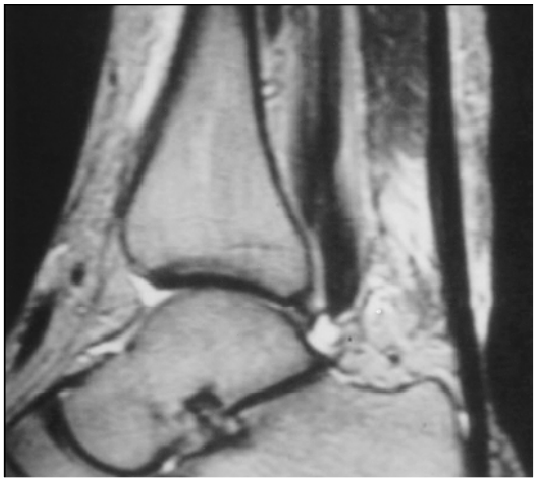

Alfredson H, Lorentzon R. Chronic Achilles tendinosis: recomendations for treatment and prevention. *Sports Med* 2000; 29:135-46

- Nos referiremos a:
  - Tendinopatias del propio tendón de etiología inflamatoria y/o traumática y/o microtraumática.
  - Rotura tendinosa, causada por un traumatismo severo o microtraumatismos.

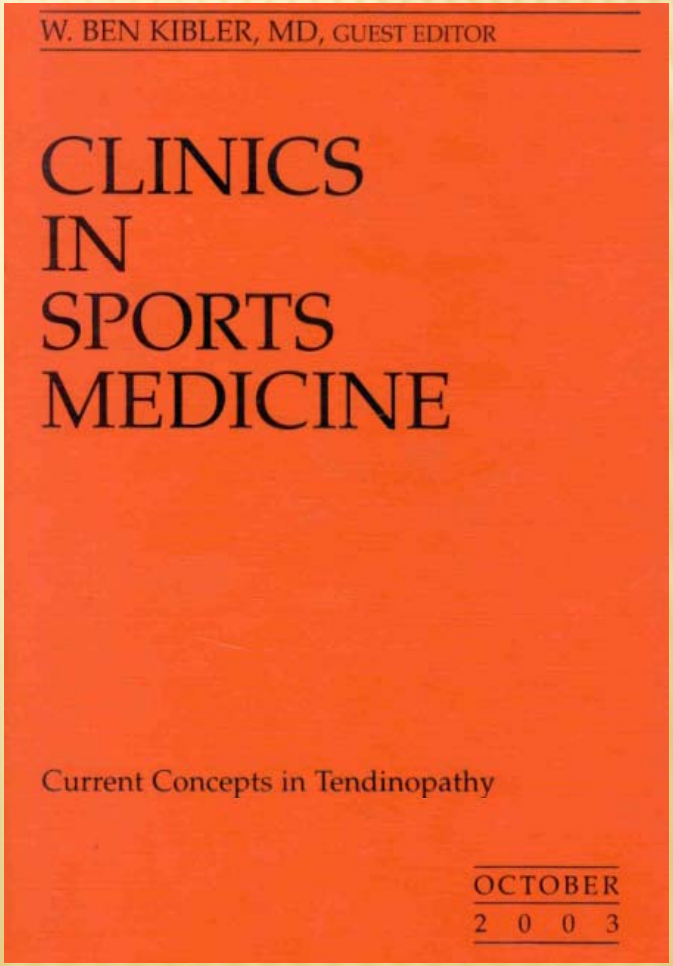

UNA VEZ LESIONADO. . . .

- En la cicatrización, es fundamental la migración y proliferación de las células tendinosas, seguidas de la síntesis y remodelación de la matriz extracelular en la zona lesionada.

NUEVAS TERAPIAS DE RECONSTRUCCION:

- Injertos:

Tabla 1
Injertos tendinosos

Zona de reparación tendinosa	Tipo de injerto		
	Autoinjertos	Aloinjertos	Sintéticos
Manguito rotador	Tensor de la fascia lata Parche de injerto fascial Ligamento coracoacromial Tendón central del cuádriceps Porción larga del bíceps Tendón rotuliano libre	Manguito rotador de cadáver Plantar	Fibra de carbono Ácido poliláctico Teflón (DuPont, Wilmington, DE) Marlex (Phillips Sumika, The Woodlands, TX) Dacrón Nylon
Tendones flexores de la mano	Palmar mayor Plantar Flexor superficial de los dedos, flexor profundo de los dedos, extensor largo de los dedos Extensores de los dedos del pie	Palmar mayor Extensores de los dedos del pie	Poliacrilamida Silicona
Tendón de Aquiles	Fascia lata Semitendinoso Recto interno Tendón rotuliano Flexor largo de los dedos	Aquiles	Ácido poliláctico Marlex Dacrón Fibra de carbono Terilene Poliacrilonitrilo

De Franco M, Derwin K, Iannotti J. J Am Acad Orthop Surg 2004;3:370-376

- Pero NO existe ningún tratamiento quirúrgico que restablezca la estructura normal de los tendones.

- Además . . . . . Complicaciones.

Tabla 2
Complicaciones de los injertos

Incapacidad de lograr resultados funcionales
Inestabilidad o alteración biomecánica articular
Rotura del injerto
Formación de adherencias
Fracaso del injerto en incorporarse al tejido natural
Reacción de cuerpo extraño (p. ej., rechazo inmunológico, antigenicidad)
Infección
Necrosis
Retraso de la cicatrización

De Franco M, Derwin K, Iannotti J. J Am Acad Orthop Surg 2004;3:370-376

FUTURO – PRESENTE:

- Aplicación principios científicos.
  - Ingeniería tisular:
    - Diseñar.
    - Construir.
    - Modificar.
    - Hacer crecer.
    - Mantener tejidos vivos.

- Objetivo:
  - Reparar o sustituir un tejido.
- Mediante:
  - Implantación de celulas, andamiajes, ADN, proteinas y/o fragmentos de proteínas.
- Nuevas tecnologias. . . . .

ANDAMIAJE:

- Estructura tridimensional biocompatible, que sirve como implante temporal o permanente. Pueden ser:
  - Biológicas.
  - Sintéticas.

BIOLOGICAS:

- El componente más importante de la matriz extracelular referente a la reconstrucción tendinosa es el colágeno tipo I.
- Colágeno tipo I es el componente estructural de los tendones y responsable de su resistencia mecánica.

SINTETICAS:

- No biodegradable:
  - Actualmente polímeros sintéticos…problemas.
- Biodegradables:
  - Materiales quirúrgicos biodegradables (suturas, bandas, parches,…).

En estudio para mejorar.

Diversos grados de éxito.

REFUERZO DE LOS ANDAMIOS

Técnicas de aumentación o refuerzo:

- Terapia celular: cultivo invitro de los andamiajes, incorporando las células cultivadas.
- Células madres mesenquimales (MSC)
- Tenocitos.
- Fibroblastos.

- Factores de crecimiento específico en fase de experimentación con conejos y corderos.
- A título de ejemplo:
  - “Proteína morfogenética 2 estimula la cicatrización de los defectos tendinosos de Aquiles en conejos”.

Forslund C, Aspenberg P: Improved healing of transected rabbit Achilles tendonafter a single injectión of cartilagederived morphogenetic protein-2. Am J Sports Med 2003;31:555-559.

TERAPIA GENICA.

- Inducir la producción local de sustancias terapéuticas.
- Consiste en la transferencia de un gen determinado al interior del acido ribonucleico mensajero (ARNm). Después, los ribosomas celulares traducen el ARNm dentro de una citoquina (proteina que influye en el comportamiento celular).
- Resultados prometedores en investigación.

Musgrave DS, Fu FH, Huard J: Genetherapy and tissue engineering in orthopaedic surgery. J Am Acad Orthop Surg 2002;10:6-15

Treatment of Tendon and Muscle Using Platelet-Rich Plasma

Allan Mishra, MD[a,*], James Woodall, Jr., MD[b], Amy Vieira, PA-C[a]

KEYWORDS

• Platelet-rich plasma • PRP • Growth factors • Tendon • Muscle • Tendonitis

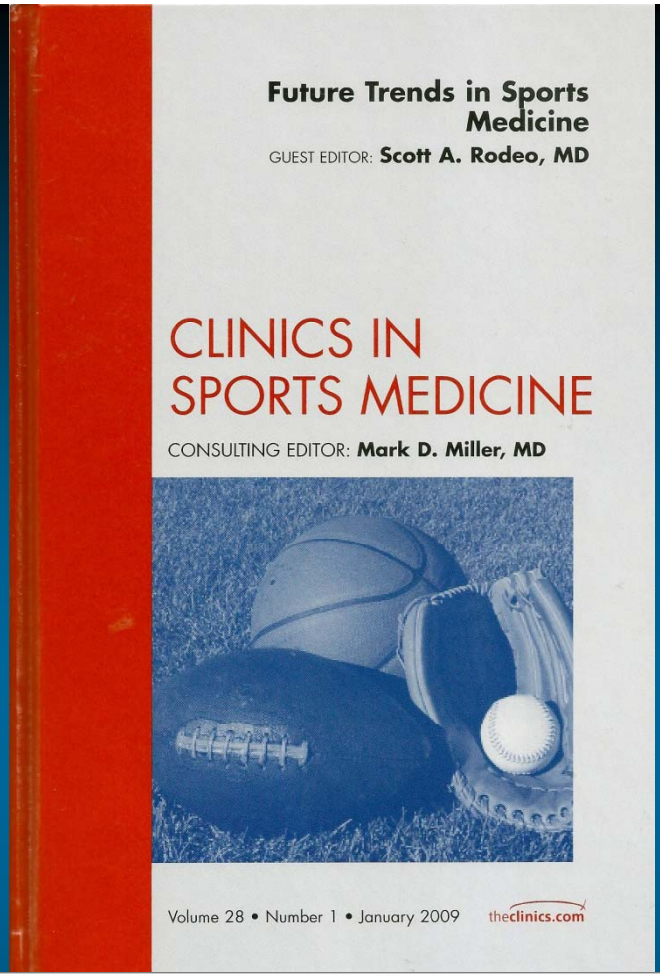

SUMMARY

In summary, PRP has emerged as a promising, but not proven, treatment option for tendon and muscle injuries and disorders. Basic science and animal investigation have begun to help in understanding the mechanism by which PRP affects tissue restoration. Because PRP is autologous and is prepared at the point of care, it also has an excellent safety profile. It may have the ability to transform the care of muscle and tendon injuries in both elite and recreational athletes. Well-designed prospective randomized trials will be required to best understand how, when, and where to use PRP most effectively.

October 2009
Vol 17, No 10
www.jaaos.org

Orthopaedic Advances

Platelet-rich Plasma: Current Concepts and Application in Sports Medicine

Abstract

Platelet-rich plasma is defined as autologous blood with a concentration of platelets above baseline values. Platelet-rich plasma has been used in maxillofacial and plastic surgery since the 1990s; its use in sports medicine is growing given its potential to enhance muscle and tendon healing. In vitro studies suggest that growth factors released by platelets recruit reparative cells and may augment soft-tissue repair. Although minimal clinical evidence is currently available, the use of platelet-rich plasma has increased, given its safety as well as the availability of new devices for outpatient preparation and delivery. Its use in surgery to augment rotator cuff and Achilles tendon repair has also been reported. As the marketing of platelet-rich plasma increases, orthopaedic surgeons must be informed regarding the available preparation devices and their differences. Many controlled clinical trials are under way, but clinical use should be approached cautiously until high-level clinical evidence supporting platelet-rich plasma efficacy is available.

Journal of the AAOS
AMERICAN ACADEMY OF ORTHOPAEDIC SURGEONS

Editorial
601 Orthopaedic Advances

Orthopaedic Advances
602 Platelet-rich Plasma: Current Concepts and Application in Sports Medicine

Review Articles
609 Adult Isthmic Spondylolisthesis
618 Pediatric Musculoskeletal Infection: Trends and Antibiotic Recommendations
627 Superior Labral Tears of the Shoulder: Pathogenesis, Evaluation, and Treatment
638 The Efficacy and Duration of Intra-articular Corticosteroid Injection for Knee Osteoarthritis: A Systematic Review of Level I Studies
647 Failure of Fracture Plate Fixation

On the Horizon From the ORS
658 How Does Sterile, Nonbiologic Implant Debris Cause Inflammation?
Cartilage Repair Strategies: Is Articular Cartilage Truly a Closed System?
The Use of Cytokine Sequencing Designed To Fill Bone Defects

S
AMERICAN ACADEMY OF ORTHOPAEDIC SURGEONS

Peer Reviewed. *Practice Focused.*

Table 3

Clinical Evidence for Use of Platelet-rich Plasma in Sports Medicine

Study	Area of Treatment	Study Type (level of evidence)	No. of Patients	PRP system	Results
Nonsurgical					
Mishra and Pavelko[17]	Lateral and medial epicondylitis	Prospective cohort (II; 10 patients randomized)	20	GPS III (Biomet, Warsaw, IN)	60% versus 16% VAS improvement at 8 wk; 93% improvement at mean 25.6 mo
Gosens et al (unpublished preliminary data, cited in Mishra et al[23])	Lateral epicondylitis	Randomized controlled trial (I)	100	GPS III (Biomet)	Improved VAS and DASH compared with corticosteroid injection at 6 mo
Kon et al[24]	Patellar tendinopathy	Prospective cohort (II)	20	Not reported	70% with complete or marked improvement; 80% satisfied
Barrett and Erredge[25]	Plantar fasciitis	Retrospective cohort (IV)	9	Not reported	Seven of nine patients with complete pain relief at 1 year
Sánchez et al[26]	Muscle injury	Prospective cohort (II)	20	PRGF System (BTI, Victoria, Spain)	Full recovery in all patients in half the expected time
Sánchez et al[27]	Knee osteoarthritis	Retrospective cohort (IV)	30	PRGF System (BTI)	Improved pain and WOMAC scores versus HA injections at 5-wk follow-up
Surgical					
Sánchez et al[20]	Achilles tendon repair	Case-control (III)	12	PRGF System (BTI)	Faster return of ROM, jumping and jogging compared with controls. No wound complications
Randelli et al[28]	Rotator cuff repair	Prospective cohort (II)	14	GPS II (Biomet)	All pts improved VAS, Constant, and UCLA scores at 2 yr. No adverse effects
Everts et al[29]	Open subacromial decompression	Randomized controlled trial (I)	40	GPS III (Biomet)	Faster recovery, earlier return to daily activities, less pain medication requirements
Orrego et al[30]	Anterior cruciate ligament reconstruction	Randomized controlled trial (II)	108	GPS II (Biomet)	Reduced MRI signal intensity in graft at 6 mo. No difference in tunnel widening or bone-tendon interface
Silva and Sampaio[31]	Anterior cruciate ligament reconstruction	Prospective cohort (II)	40	Mini GPS III (Biomet)	No difference in MRI signal intensity at 3 mo
Sánchez et al[32]	Articular cartilage defect	Case report (V)	1	PRGF System (BTI)	Improved pain and return to activity

DASH = Disabilities of the Arm, Shoulder, and Hand questionnaire; HA = hyaluronic acid; PRP = platelet-rich plasma; ROM = range of motion; UCLA = University of California, Los Angeles; VAS = visual analog scale; WOMAC = Western Ontario and McMaster Universities Osteoarthritis Index

Últimos datos.

Tendencia actual de los estudios en tratamientos quirurgicos.

- **Fuerzas que actúan son diversas.**

  - Tracción.
  - Pinzamientos.
  - Rozamientos.

Rotuliano. Aquiles.
Manguito rotador.
Tibial posterior.
Peroneos.

Repeated Exposure of Tendon to Prostaglandin-E_2 Leads to Localized Tendon Degeneration

Mustafa H. Khan, MD, Zhaozhu Li, MD, and James H.-C. Wang, PhD (*Clin J Sport Med* 2005;15:27–33)

CLINICS IN SPORTS MEDICINE

Clin Sports Med 22 (2003) 743–759

Patellar tendinopathy

Stuart J. Warden, BPhysio (Hons), PhD[a,b],
Peter Brukner, MBBS, FACSP[a,*]

[a]*Centre for Sports Medicine Research and Education, The University of Melbourne, Victoria 3010, Australia*
[b]*Department of Orthopedic Surgery, Indiana University School of Medicine, 1120 South Drive, Indianapolis, IN 46202-5114, USA*

Results of MRI assessment in symptomatic and asymptomatic patellar tendons

		Symptomatic tendons				Asymptomatic tendons			
	Total tendons	Total	+	–	+/–	Total	+	–	+/–
Davies et al [27]	16	16	14	0	2	0			
Johnson et al [32]	38	24	19	5		14	0	14	
Khan et al [10]	63	28	28	0		35	nr	nr	
Major and Helms [60]	34	0				34	8	26	
McLoughlin et al [64]	15	15	15	0		0			
Popp et al [19]	11	11	11	0		0			
Schmid et al [35]	51	19	18	1		32	23	9	
Shalaby and Almekinders [34]	29	12	7	3	2	17	4	5	8
Yu et al [14]	11	11	11	0		0			
Summary	252	120	109	9	2	132	35	54	0

Calculations
Sensitivity = 78%
Specificity = 86%
Positive predictive value (PV+) = 93%
Negative predictive value (PV–) = 61%
Abbreviations: +, positive ultrasonography finding; –, negative ultrasonography finding; +/–, unequivocal ultrasonography finding; nr, not reported.

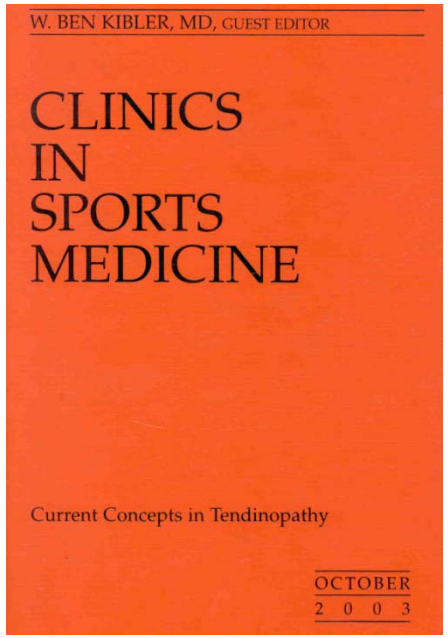

2003

CLINICS IN SPORTS MEDICINE

Clin Sports Med 22 (2003) 743–759

Patellar tendinopathy

Stuart J. Warden, BPhysio (Hons), PhD[a,b],
Peter Brukner, MBBS, FACSP[a,*]

[a]*Centre for Sports Medicine Research and Education, The University of Melbourne, Victoria 3010, Australia*
[b]*Department of Orthopedic Surgery, Indiana University School of Medicine, 1120 South Drive, Indianapolis, IN 46202-5114, USA*

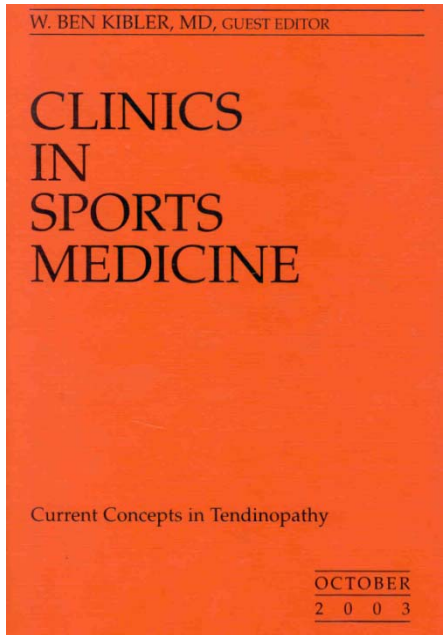

2003

Surgical treatment

Surgery for patellar tendinopathy is only indicated after a prolonged (6 months) and well-supervised conservative treatment program fails. Surgery may involve excision of degenerated areas, arthroscopic debridement, repair of macroscopic defects, multiple longitudinal tenotomies, drilling of the inferior pole of the patella, resection of the tibial attachment of the patellar tendon with realignment, percutaneous needling, or percutaneous longitudinal tenotomy [29,41]. As the pathophysiology of patellar tendinopathy is not known, the exact surgical technique chosen is based on the surgeon's opinion and experience [29]. There is no consensus as to the optimal surgical technique to use.

Surgery is not indicated in the initial management of patellar tendinopathy, as surgical outcomes are rather unpredictable and recovery can be extended. A review of 23 papers found that the outcome following surgery was either excellent or good in 46% to 100% of cases, with an overall success rate of 75% to 85% being a very-best-case estimate [96]. Thus, 15% to 25% of patients will experience persistent or recurrent tendon pain following surgery. The recovery following surgery, even with a good or excellent result, can take 6 to 12 months [40,57], and many athletes will not be able to return to their previous level of sport [97]. Consequently, surgery should only be considered after a thorough, high-quality, conservative management program has been attempted.

Surgical Treatment of Chronic Patellar Tendinosis

A Systematic Review

Christopher C. Kaeding, MD; Angela D. Pedroza, BS; and Bret C. Powers, DO

2006

CLINICAL ORTHOPAEDICS AND RELATED RESEARCH
Number 455, pp. 102–106
© 2006 Lippincott Williams & Wilkins

TABLE 1. Demographics on the Articles Included in the Systematic Review

Authors	Study Design (case series)	N Tendons	Age (years)	Gender (male:female)	Time of Followup (years)	Percent Success	Percent Followup	Percent Return to Sport
Fritschy and Wallensten[6]	Prospective	21	26	19:2	1–7	95	—	81
Al-Duri and Aichroth[1]	Retrospective	18	30	12:5	0.5–2	94	100	—
Coleman et al[2]	Retrospective	54	—	—	mean 4.1	96	93	50
Ferretti et al[5]	Retrospective	32	26.9	24:3	5–11	85	84	82
Karlsson et al[9]	Retrospective	86	25	72:6	2–15	91	91	91
Khan et al[10]	Prospective	15	31	13:0	1	85	100	—
	Retrospective	18	27	16:1	mean 3.9	89	100	—
Pierets et al[14]	Retrospective	26	31	17:9	mean 4.2	50	100	15.8
Popp et al[15]	Retrospective	11	20.2	8:1	mean 2.1	91	100	91
Verheyden et al[18]	Retrospective	31	29	27:2	3–6	87	100	87
Mean			27	24:3	5.35	87.47	94.28	71.28

" MUCHOS ARTÍCULOS Y POCO CONSENSO "

- 30 articulos.
- Mayoría de estudios retrospectivos y con técnicas diferentes.
- Medidas de seguimiento y resultados diferentes en todos los estudios.
- No homogeneidad.

" MUCHOS ARTÍCULOS Y POCO CONSENSO "

- **Técnica quirúrgica:**
  - Acción sobre polo inferior rotula: 70.9% éxitos
  - No acción sobre polo inferior: 91.7% éxitos.

- **Cierre del paratendón:**
  - Sí: 84.8% éxitos.
  - No: 91.5% éxitos.

" MUCHOS ARTÍCULOS Y POCO CONSENSO "

- **Inmovilización:**
  - **Sí (4 estudios): 82.4% éxitos.**
  - **No (3 estudios): 94.9% éxitos.**
  - **Resto de estudios (23): No especifican este punto.**

" MUCHOS ARTÍCULOS Y POCO CONSENSO "

- ¿Qué técnica se emplea?
  - De los 30 estudios sólo 2 tienen la misma técnica descrita.
    - Poblaciones diferentes en estos estudios

TENDON ROTULIANO

- **TENDINOSIS ROTULIANA.**
- **ROTURA AGUDA.**
- **ROTURA CRONICA.**



1983

TABLA 33. *Tipo de tratamiento y resultado de 13 pacientes operados en la Clínica Ortopédica de Munich por una ruptura o avulsión del tendón patelar. (Las indicaciones sobre movilidad se refieren a la rodilla comprometida, sobre fuerza al músculo cuadriceps y sobre hipotrofia del cuadriceps a la diferencia con el lado sano)*

Caso N.º Nombre Edad Sexo	Plazo lesión/ operación	Tratamiento operatorio	Plazo operación/ control	Resultado objetivo					Resultado subjetivo		
				Movilidad	Fuerza	Atrofia del cuadriceps	Rótula alta	Artrosis de la rótula	Satisfecho	Dolor al apoyar	Deporte
1. B. K. 54, ♀	2 años	Refijación en la tuberosidad	9 años	0-0-110	Buena	No	No	Leve	Si	Si	No
2. W. H. 32, ♂	2 días	Refijación en la rótula	6 años	Libre	Buena	−1,5 cm	No	Leve	Si	No	Si
3. D. L. 33, ♂	6 semanas	Refijación en la rótula	6 años	0-0-130	Buena	−1,5 cm	No	Mediana	Si	No	Si
4. D. L. 35, ♂	1 día	Refijación en la rótula	4 años	0-0-130	Buena	No	No	Moderada	Si	No	Si
5. G. J. 32, ♂	Inmediata	Sutura terminoterminal	4 años	0-0-120	Moderada	−7 cm	No	Moderada	Si	No	Si
6. S. P. 13, ♂	9 días	Refijación en la tuberosidad	4 años	0-0-135	Buena	−1,5 cm	No	No	Si	No	Si
7. K. A. 45, ♂	4 semanas	Sutura terminoterminal	3 años	0-0-110	Buena	−1,5 cm	No	Mediana	Si	Si	No
8. D. R. 26, ♂	Inmediata	Sutura terminoterminal. Duramadre	2 años	0-0-120	Moderada	−2,5 cm	Si	Moderada	Si	Si	Si
9. F. E. 57, ♀	12 días	Sutura terminoterminal	2 años	0-10-100	Buena	No	No	No	Si	No	Si
10. K. H. 38, ♂	1 día	Sutura terminoterminal	2 años	0-0-130	Buena	No	Si	Moderada	Si	Si	Si
11. F. H. 25, ♂	2 años	Plicatura	1 año	Libre	Buena	−4 cm	Si	Leve	Si	Si	No
12. S. F. 60, ♂	3 días	Refijación en la rótula	1 año	0-5-100	Moderada	−2 cm	No	Marcada	No	Si	No
13. S. J. 26, ♂	1 día	Sutura terminoterminal		Libre	Buena	−2 cm	No	No	Si	No	Si

TENDON ROTULIANO

- **TENDINOSIS ROTULIANA.**
- **ROTURA AGUDA.**
- **ROTURA CRONICA.**

TENDON ROTULIANO

- **TENDINOSIS ROTULIANA.**
- **ROTURA AGUDA.**
- **ROTURA CRONICA.**

- **Fuerzas que actúan son diversas.**

  - Tracción.
  - Pinzamientos.
  - Rozamientos.

Rotuliano. Aquiles.
Manguito rotador.
Tibial posterior.
Peroneos.

Repeated Exposure of Tendon to Prostaglandin-E_2 Leads to Localized Tendon Degeneration

Mustafa H. Khan, MD, Zhaozhu Li, MD, and James H.-C. Wang, PhD (*Clin J Sport Med* 2005;15:27–33)

TRANSTORNOS DE LOS PERONEOS

- CLASICAMENTE CUATRO TIPOS



Update on diseases and treatment of the peroneal tendon, including peroneal tendon tear, subluxing peroneal tendon, and tendinosis

Matthew R. Steensma, John G. Anderson and Donald R. Bohay

Current Opinion in Orthopaedics 2005, 16:60–64

Currently, evidence is accumulating that supports a surgical approach to the management of peroneal tendon abnormalities. Appropriate conservative treatment must be considered, but reporting of successful surgical outcomes continues. Success in treating subluxating peroneal tendons appears to be related to a combined approach that addresses the major etiologic factors: SPR insufficiency, fibular groove morphology, malalignment, and associated lateral-sided conditions such as instability. Peroneal tendon tears can be managed with a combination of debridement, repair, and augmentation. If necessary, offending malalignment should be addressed at the time of surgery. Overall, excellent results can be expected in the treatment of peroneal tendon abnormalities.



Update on diseases and treatment of the peroneal tendon, including peroneal tendon tear, subluxing peroneal tendon, and tendinosis

Matthew R. Steensma, John G. Anderson and Donald R. Bohay

Figure 1. Oden's surgical classification of superior peroneal retinaculum injuries

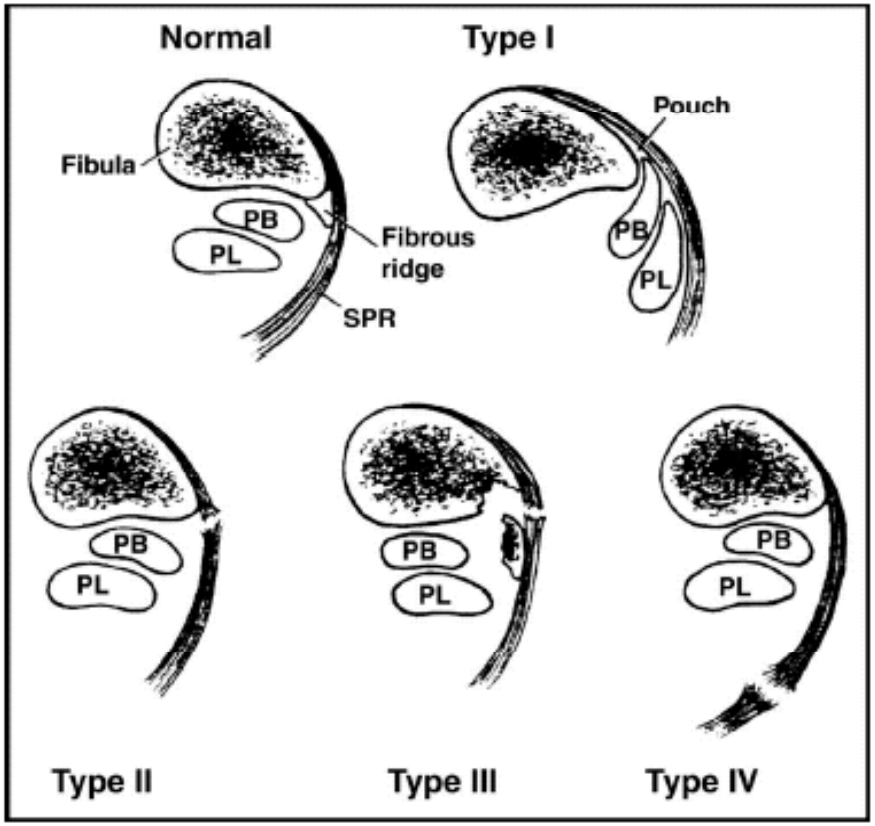

Current Opinion in Orthopaedics 2005, 16:60–64

TRATAMIENTO

TIPOS DE DESGARROS

- **Tercio anterior** si el fragmento roto está delustrado o es pequeño→ Exéresis del tercio anterior.
- **Tercio Medio**→ **Reparar** el tendón con sutura no reabsorbible.
- **Tendón Completo** y si existe una delustración importante → **Exéresis** del segmento degenerado y tenodesis al peroneo largo de ambos extremos.

- TENDINOPATIA PERONEA:

  - SIN INESTABILIDAD.

  - CON INESTABILIDAD.

  - ESTENOSANTE PERONEO LARGO.
    - PERONEO ACCESORIO.

  - LUXACION TRAUMATICA AGUDA.

Tendinopatia peronea sin inestabilidad

- Desbridamiento…

- Reparación…

- Y tenosinovectomia

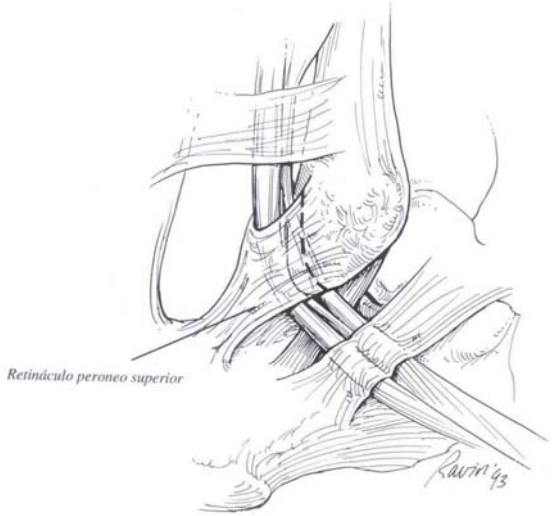

Tendinopatia peronea con inestabilidad

- **RESPETAR** los pediculos sinoviales y vasculares posterolaterales.
- **RECONSTRUIR** anatómica y cuidadosamente el retináculo peroneo superior.
- **RESECAR** tejido anómalo dentro del surco.
- **REPRODUCIR** la estabilidad del tobillo.

DIFERENTES TECNICAS

FIG. 137. Aspecto clínico de una luxación habitual de los tendones peroneos.

Lannelongue, 1890

Kelly, 1920

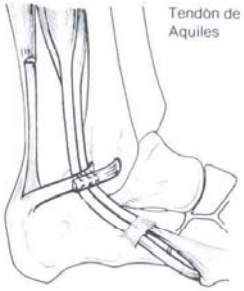

Jones, 1932

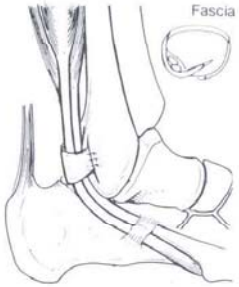

v. Muralt, 1956

Platzgummer, 1967

Leitz, 1968

Viernstein, 1968

Superior Peroneal Retinaculoplasty: A Surgical Technique for Peroneal Subluxation

Virak Tan, MD; Sheldon S. Lin, MD*; and Enyi Okereke, PharmD, MD***

CLINICAL ORTHOPAEDICS AND RELATED RESEARCH
Number 410, pp. 320–325
© 2003 Lippincott Williams & Wilkins, Inc.

A modification of a soft tissue reconstruction procedure for treatment of peroneal tendon subluxation and dislocation is presented. The procedure is based on creating one periosteal flap from the posterior fibula in the region of the peroneal groove. The flap is used to reinforce the superior peroneal retinaculum and prevent anterior displacement of the tendons. This reconstructive procedure has several advantages over existing procedures. The major advantage is that it recreates the normal anatomy of the superior peroneal retinaculum with little disturbance of the surrounding tissues. In addition, the procedure is simple and can be done relatively quickly for patients with acute and chronic subluxation and/or dislocation. Finally, because metallic hardware (such as screws or suture anchors) is not used, artifacts are minimized on magnetic resonance imaging scans.

Superior Peroneal Retinaculoplasty: A Surgical Technique for Peroneal Subluxation

Virak Tan, MD; Sheldon S. Lin, MD*; and Enyi Okereke, PharmD, MD***

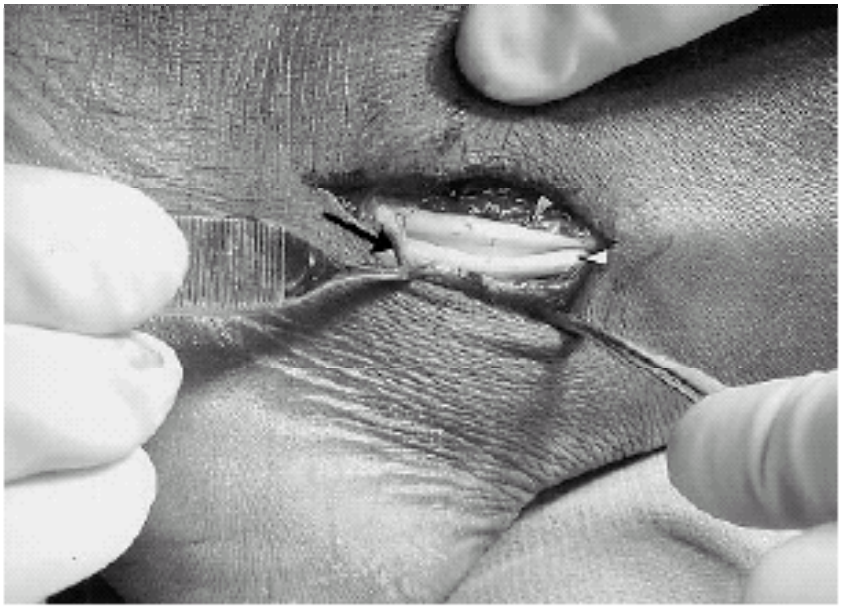

Fig 1. An intraoperative photograph of a left ankle (lateral approach) shows the peroneal tendons (brevis-grey arrow; longus-white arrow) are subluxating anterolaterally over the distal fibula. The superior peroneal retinaculum (black arrow), held by the forceps, is deficient, especially anteriorly.

Fig 2. The peroneal tendons have been retracted anteriorly by the Penrose drain. Elevation of an anterior-based periosteal flap (outlined by dots) from the fibular groove has been done. The remnant superior peroneal retinaculum (black arrow) is posterior.

Superior Peroneal Retinaculoplasty: A Surgical Technique for Peroneal Subluxation

Virak Tan, MD; Sheldon S. Lin, MD*; and Enyi Okereke, PharmD, MD***

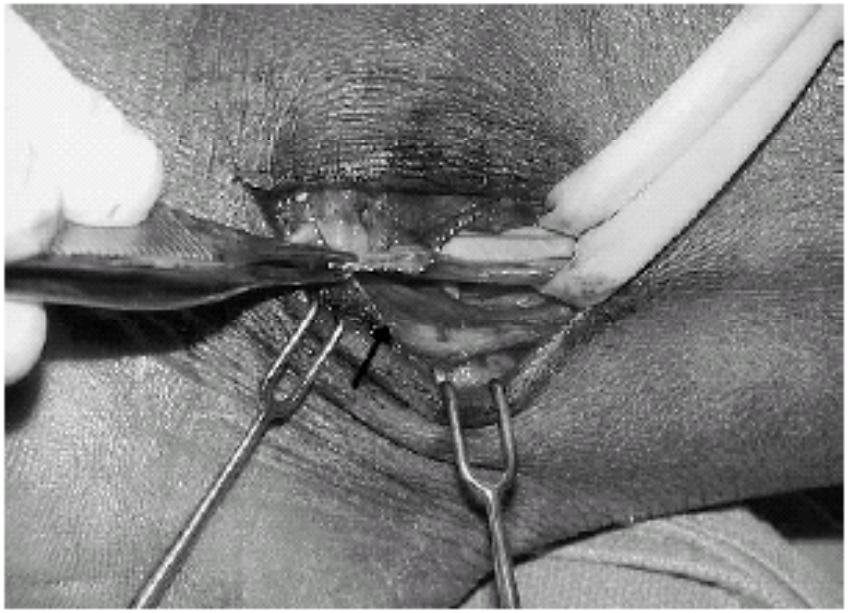

Fig 3. After groove deepening, the tendons are relocated within the newly created groove. The anterior-based periosteal flap (outlined by dots) then is brought over the tendons to reinforce the remnant superior peroneal retinaculum (black arrow).

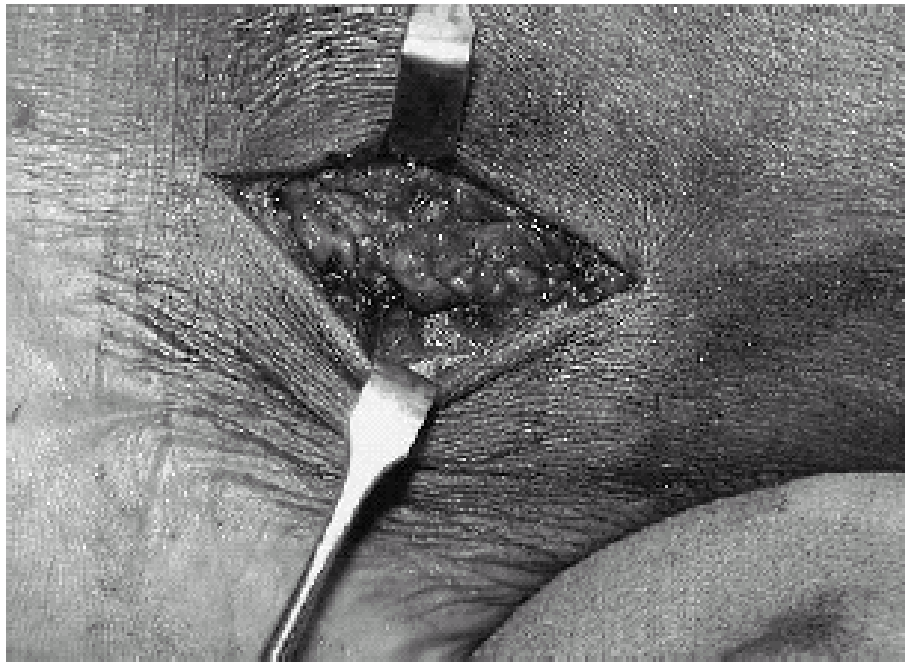

Fig 4. The flap is sutured to the remnant superior peroneal retinaculum with nonabsorbable sutures completing the superior peroneal retinaculoplasty.

TTO. Q.

- Tendinopatia peronea sin inestabilidad.
- Tendinopatia peronea asociada a inestabilidad.
- Tenosinovitis estenosante.
- Peroneo accesorio.
- Luxación traumática aguda.

- **Fuerzas que actúan son diversas.**

  - Tracción.
  - Pinzamientos.
  - Rozamientos.

Rotuliano. Aquiles.
Manguito rotador.
Tibial posterior.
Peroneos.

Repeated Exposure of Tendon to Prostaglandin-E_2 Leads to Localized Tendon Degeneration

Mustafa H. Khan, MD, Zhaozhu Li, MD, and James H.-C. Wang, PhD (*Clin J Sport Med* 2005;15:27–33)

- Cuadricipital.

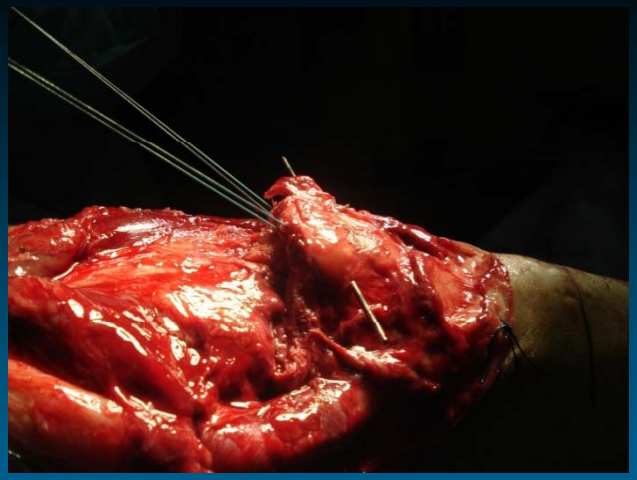

- T. Pata de ganso.

- L. Desfiladeros de la muñeca

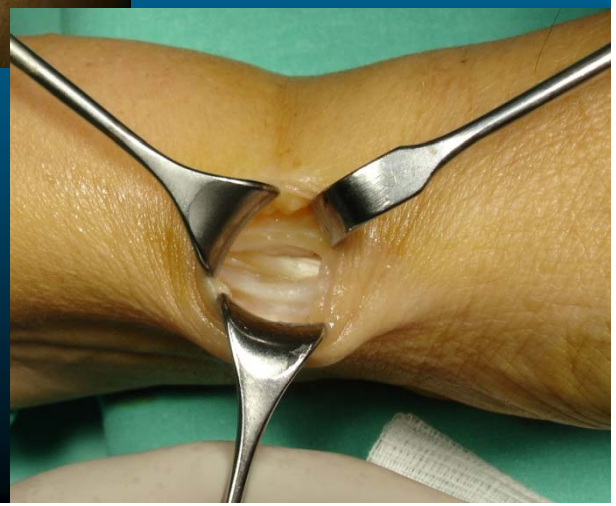

- **“El arte del tratamiento de la tendinopatía consiste en ser capaz de enseñar al paciente a sobrecargar de manera moderada sus tendones y aumentar progresivamente dicha carga hasta la mejora de la función tendinosa”.**

www.trauma.cursos-valenciaport.com